

NEPHROPROTECTIVE EFFECT OF *AMARANTHUS SPINOSUS* ROOT EXTRACT IN CARBON TETRACHLORIDE INDUCED TOXICITY IN MALE ALBINO RAT

KENGAR, S.,¹ THORAT, D.² AND JADHAV, J.³

¹Department of Zoology, Yashwantrao Chavan College of Science Karad 415124 (MH);

²Department. of Zoology, Balasaheb Desai College, Patan, 415206 (MH); ³Cell Biology Section, Department of Zoology, Shivaji University, Kolhapur, 416 004 (MH).

E. mail: sbkengar@ymail.com, Cell: 09850571346

Received: April 7, 2017; Revised: April 11, 2017; Accepted: April 25, 2017

Abstract: *In the present study, ethanol extract of Amaranthus spinosus root was investigated for protective activity in CCl₄ induced nephrotoxicity in male albino rat by histological assessment. CCl₄ induced intoxicated rats were treated with 150, 300 and 450mg/kg body wt dose of ethanol extracts of A. spinosus in 15 days experimental schedule. The results revealed the deleterious histopathological alterations in kidney associated with glomerular and tubular degenerations in CCl₄ intoxicated rat. Treatment of A. spinosus roots especially at 450 mg dose protects the kidney by improving disrupted metabolisms and antioxidant defense against CCl₄ induced oxidative damage in 15 days protective experimental schedule. The findings support the therapeutic use of A. spinosus in ailments caused by oxidative and altered metabolisms.*

Key words: *Amaranthus spinosus*, CCl₄, Nephrotoxicity

INTRODUCTION

Oxidative stress in cells and tissues result from the increased generation of free radicals or reactive oxygen species (ROS) [1,2]. Free radicals are produced in cells by cellular metabolism and by exogenous agents that induce numerous pathological complications [3-5]. Carbon tetrachloride (CCl₄), a commonly used hepatotoxin in experimental models to induce oxidative stress. It is known to induce free radicals in liver and kidney and cause cellular damage [6-8]. The kidneys are responsible for elimination of unmodified drugs and metabolites. The certain metabolites accumulated in the kidney induce nephrotoxicity. It reportedly gets distributed at higher concentrations in the kidney leading to renal damage [9-11]. It shows a high affinity to the cortex which contains predominantly cytochrome P-450 [12,13].

The ingredients with antioxidant activity that acts as a free radical scavengers have a great potential to protect oxidative damage.

Amaranthus spinosus Linn. (Family Amaranthaceae), commonly known as “pig weed” is known for its several pharmacological properties. It is used as anti-inflammatory, anti-malarial, antibacterial, anti-diuretic, antiviral and hepatic disorders. The studies on *A. spinosus* have been carried out by various researchers and a wide spectrum of its pharmacological actions have been explored which may include antinephritic, antidiabetic, antitumor, analgesic, antimicrobial, anti-inflammatory, spasmolytic, bronchodilator, hepato-protective, spermatogenic, antifertility, antimalarial and antioxidant properties, etc [14-20]. Phytochemical investigations revealed the presence of several active

constituents like alkaloids, flavonoids, glycosides, phenolic acids, steroids, amino acids, terpenoids, lipids, saponin, betalain, b-sitosterol, stigmasterol, linoleic acid, rutin, catechuic tannins and carotenoids [16,21,22].

The reported hepatoprotective, antioxidative, antidiabetic activity of the root extract of *A. spinosus* prompted us to investigate protective efficacy of ethanolic root extracts of this plant in CCl₄ induced oxidative damage in kidney of male albino rat through histological assessment.

MATERIALS AND METHODS

Plant material and preparation of extracts: The fresh root of *A. spinosus* were obtained from the rural area of the Karad (Dist. Satara, MH, India) and were properly identified. The roots were washed, shed dried and powdered mechanically with standard method. The root powder was extracted with ethanol. The dissolved extracts were filtered through Whatman filter paper (No.1). Supernatants of each extracts were evaporated at 60° C to dryness. After evaporation extracts were collected and stored at 4°C. To study the effects of ethanolic root extracts of *A. spinosus* on kidney different doses viz; 150, 300 and 450 mg/kg body wt were used.

Experimental design: Male albino rats, *Rattus norvegicus* (Wistar strain) weighing 180-220g were used for the experiments. The rats were acclimatized under standard laboratory condition and were fed with

standard pellet diet (Amrit feeds, Sangli, Maharashtra). Animals were randomly allocated into six groups of six each as per various treatments given as follows:

Group I: Normal rats without any treatment.

Group II: Acute hepatotoxicity induced by administration of 3.0 ml CCl₄ /kg body wt/day for 15 days *subcutaneously*.

Group III: 3.0 ml CCl₄/kg body wt/day for 15 days (sc) + 50 mg dose of *A. spinosus* root extract/kg body wt. for 15 days simultaneously.

Group IV: 3.0 ml CCl₄/kg body wt/day for 15 days (sc) + 150 mg dose of *A. spinosus* root extract/kg body wt. for 15 days simultaneously.

Group V: 3.0 ml CCl₄/kg body wt/day for 15 days (sc) + 300 mg dose of *A. spinosus* root extract/kg body wt. for 15 days simultaneously.

Group VI: 3.0 ml CCl₄/kg body wt/day for 15 days (sc) + 450 mg dose of *A. spinosus* root extract/kg body wt. for 15 days simultaneously.

Histological preparation: At the end of experimental period, all the animals were sacrificed and kidney were dissected out immediately and processed for histological assessment. Tissues were fixed in **calcium acetate formalin** and processed for paraffin sectioning as per routine microtechnique. The specimens were washed and dehydrated in ascending grades of alcohol. Then cleared and embedded in paraffin. The paraffin sections of 5 µm thickness were cut and stained with haematoxylin-eosin. The sections were observed under light microscope for histopathological alterations in tissue

Explanations of figures

Figures 1 to 8 show T.S. of rat kidney stained with haematoxylin-eosin.

Fig. 1: Normal kidney cortex showing normal glomeruli with Bowman's capsule. Proximal tubules with brush borders and distal tubules were with distinct lumina.

Fig. 2: Medulla region of normal kidney showing differentiated stromal and interstitial tissues.

Fig. 3: CCl₄ intoxicated rat kidney showing glomerular congestion, disintegrated Bowman's capsules and swollen proximal tubules with loss of brush borders.

Fig. 4: CCl₄ treated medulla showing thickening of collecting tubules with interstitial oedema.

Fig. 5: Treatment of 150mg *A. spinosus* root extract showing dilated glomeruli with collapsed Bowman's capsule.

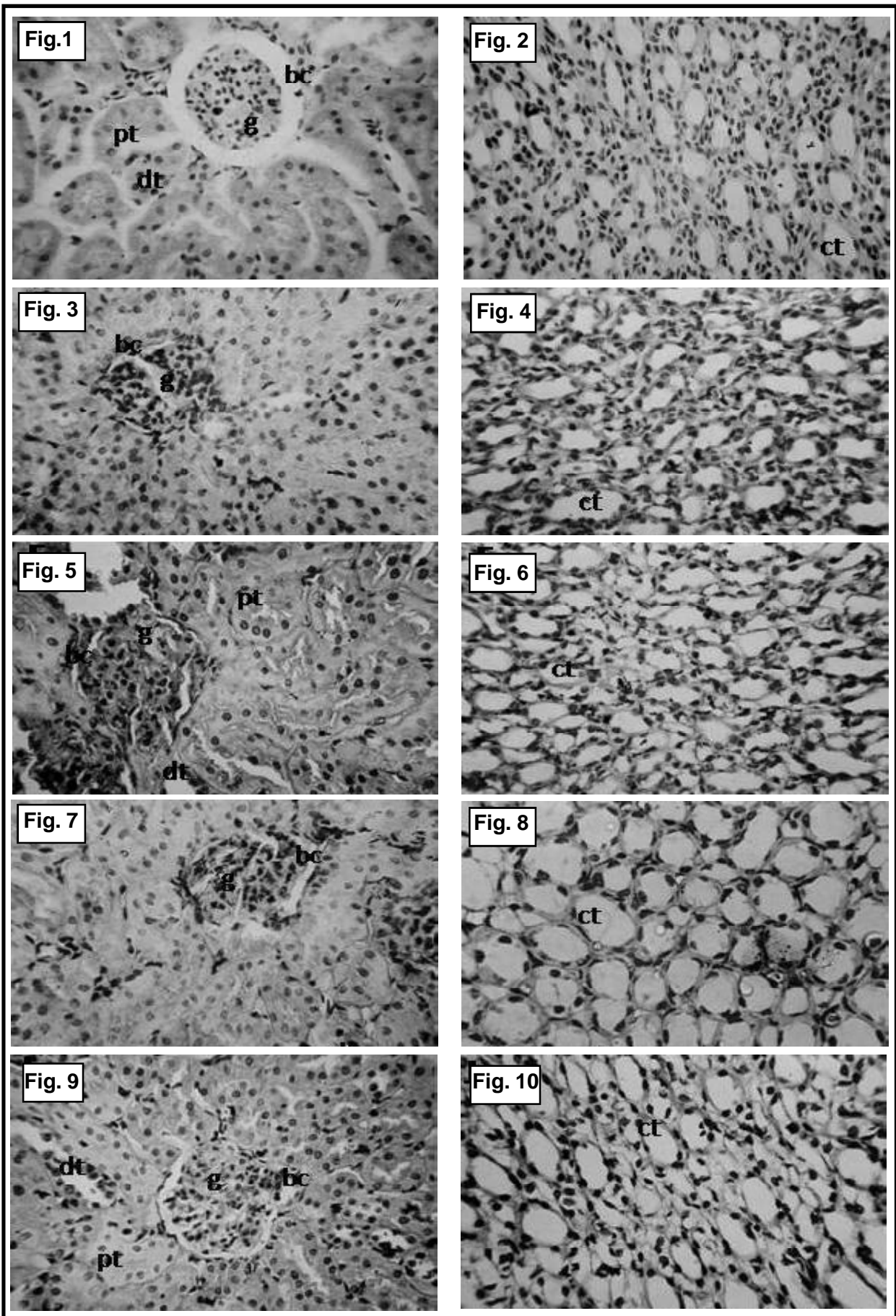
Fig. 6: 150mg dose of *Amaranthus spinosus* root extract showing thickened basement membrane of collecting tubules.

Fig. 7: Treatment of 300mg *A. spinosus* root extract showing normal glomeruli with distinct lumina of proximal and distal tubules.

Fig. 8: 300mg dose treated medulla region showing normal collecting tubules with reduced trafficking cells.

Fig. 9: Treatment of 450mg dose of *A. spinosus* root exhibited protected kidney histology, associated with normal glomerulus, Bowman's capsules. Proximal and distal tubules were clear lumina.

Fig. 10: Normal medulla region with well identified stromal and interstitial tissue. Collecting tissues with normal nuclear staining.



RESULTS AND DISCUSSION

Several studies have showed that plants possessing free radical scavenging properties could be playing an important role in protection of oxidative damages in different organs such as liver, kidney, brain; caused by environmental and chemical toxicants through metabolic activation to highly reactive substances such as free radicals. In the present study *A. spinosus* roots extracts in ethanol was tested for protective efficacy against CCl_4 induced kidney damage in male albino rat.

The histological observation of the kidney of normal rat revealed the normal cortex and medulla region. It showed normal glomeruli (g) with Bowman's capsule (bc). Endothelial cells were normal. The proximal tubules (pt) with distinct lumina filled with anatomizing brush border and distal tubules (dt) was normal with clear lumina. The stromal and interstitial tissues can be differentiated (Figs. 1,2).

Administration of 3.0 ml CCl_4 /kg body wt per day for 15 days resulted marked deleterious histological changes (Figs. 3,4). It showed significant glomerular and tubular degenerations. Glomerular congestion has been observed with disintegrated Bowman's capsules. Vacuolar and degenerative changes were also evident in endothelial lining of glomerular tuft and in epithelial lining of renal tubules. Swollen proximal tubules and dilated Bowman's capsule was observed. Swollen collecting ducts, distinct intertubular connective tissue and thickening of collecting tubules are indicator of constant irritation [23].

For the protective experimental schedule three doses (150, 300 and 450 mg/kg body wt) of *Amaranthus spinosus* root extract were tested. These doses (PO) were initiated simultaneously with the CCl_4 administration. Treatment of 150 mg/kg body wt. dose of plant extract given for 15 days resulted in collapsed lumina. Bowman's capsule disintegrated. Luminas of proximal and distal tubules were not differentiated due to loss of brush border of proximal tubules. Basement membranes of tubules was thickened (Figs. 5,6).

Administration of 300mg/kg body wt. dose of *Amaranthus spinosus* root extract showed normal glomerulus (Figs. 7,8). Distinct lumina of proximal and distal tubules. Collecting tubules were observed

with reduced trafficking cells. Treatment of 450 mg/kg body wt dose of ethanol extracts of *A. spinosus* root protected normal morphology of the kidney and showed normal architecture of the kidney (Figs. 9,10). It showed normal glomerulus, cortex and medulla. It is associated with normal proximal tubules with distinct brush borders, distal tubules and collecting tubules. The collecting tubules were normal with reduced trafficking cells. Connecting tissue with normal nuclear staining. These structural improvements were also observed with the tissues treated with 300 mg dose but were comparatively in reduced form.

The observed nephroprotective effect of *A. spinosus* roots might due to the presence of phenolic and flavonoidal contents in extract that can control the oxidation. The active ingredients can control the oxidation and peroxidation process of lipids, resulting in reduction of tissue damage and help to continue the blood flow in the kidney and improvement of kidney functionality [24-26].

The results indicated that ethanolic extract of *A. spinosus* root at 450 mg dose protects the kidney from the histological alterations caused by oxidative damage; by improving disrupted metabolisms and antioxidant defense against CCl_4 induced oxidative damage in 15 days protective experimental schedule. The findings support the therapeutic application of *A. spinosus* in animals to check the oxidative damage caused by CCl_4 .

REFERENCES

- [1] Mylonas, C. and Kouretas, D.: *In vivo.*, 13(3): 295-309 (1999).
- [2] Sumida, Y., Niki, E., Naito, Y. and Yoshikawa T.: *Free Radical Res.*, 47 (11): 869-880 (2013).
- [3] Singh, P.P., Fazana, M., Roy A. and Sharma P.: *Indian J. Clin. Biochem.*, 24(4): 324-342 (2009).
- [4] Bhattacharya, A., Chattopadhyaya, R., Mitra, S. and Crowe, S.E.: *Physiol. Rev.*, 94(2): 329-354 (2014).
- [5] Trnkova, L., Drsata, J. and Bousova, I.: *J. Biosci.*, 40(2): 419-439 (2015).
- [6] Mehendale, H.M.: *Hepatic Toxicity in Modern Toxicology*. MD Metropolian publishers, New Delhi (1985).
- [7] Roullier, C.H.: *Experimental toxic injury of the liver*. In: *The Liver*, Acad. Press, New York, pp. 335-443 (1963).
- [8] Ozturk, F., Ucar, M., Ozturk, C., Vard, N. and Batcyoglu, K.: *Urology*, 62(2): 353-356 (2003).

- [9] Sanzgiri, U.Y., Srivatsan, V., Muralidhara, S., Dallas, C.E. and Bruckner, J.V.: *Toxicol. Appl. Pharmacol.*, 143(1): 120-129 (1997).
- [10] Sener, G., Sehirlı, A.O., Altunbas, H.Z., Ersoy, Y., Paskaloglu, K., Arbaks, Ayanoglu-Dugler G.: *J. Pineal Res.*, 32: 231-236 (2002).
- [11] Teli, P., Jadhav, J., Thorat, D. and Kanase A. : *J. Pharma. Res.*, 8(7): 877-883 (2014).
- [12] Jaramillo-ju'arez, F., Rodriguez-V'azquez, M.L., Rinc'on-S'anchez, A.R., Consolaci'on, M., Ortiz, G.G. and Llamas, J.: *Annals Hepatol.*, 7(4): 331-338 (2008).
- [13] Abraham, P., Wilfred, G. and Cathrine, S.P.: *Clinica Chimica Acta.*, 289 (1-2): 177-179 (1999).
- [14] Samy, R.P., Ignacimuthu, S. and Raja, D.P.: *J. Ethnopharmacol.*, 66: 235-240 (1999).
- [15] Srivastava, R., Shukla, Y.N. and Kumar, S.: *J. Med. Arom. Plant. Sci.*, 20: 762-767 (1998).
- [16] Harsha Vardhana, S.: *Pharmacophore*, 2(5): 266-270 (2011).
- [17] Berghofer, E. and Schoenlechner, R.: Grain amaranth In: *Pseudocereals and Less Common Cereals*. Grain Properties and Utilization Potential (Belton, P.S. and Taylor J.R.N. eds.), Springer, Berlin Heidelberg D, New York, pp. 219-260 (2002).
- [18] Zeashan, H., Amresh, G., Singh, S. and Rao, C.V.: *Food Chem. Toxicol.*, 46 (11): 3417-3421 (2008).
- [19] Zeashan, H., Amresh, G., Singh, S. and Rao, C.V.: *J. Ethnopharmacol.*, 125(2): 364-366 (2009).
- [20] Zeashan, H., Amresh, G., Singh, S. and Rao, C.V.: *Pharmaceutic. biol.*, 47 (10): 932-939 (2009).
- [21] Azhar-ul-Haq, M., Afzam N., Khan, S.B. and Muhammad, P.: *Polish J. Chem.*, 80: 259-263 (2006).
- [22] Blunden, G., Yang, M., Janicsak, M.I. and Carabot-Cuervo, A.: *Biochem. Systemat. Ecol.*, 27: 87-92 (1999).
- [23] Majno, G. and Joris, I.: *Principals of General Pathology*, Oxford Univ. Press, New York, (2004).
- [24] Rafieian-Kopaei, M., Baradaran, A. and Rafieian, M.: *J. Res. Med. Sci.*, 18(7): 629 (2013).
- [25] Rafieian-Kopaei, M., Baradaran, A. and Rafieian, M.: *J. Nephropathol.*, 2(2): 152-153 (2013).
- [26] Baradaran, A., Nasri, H., Nematbakhsh, M. and Rafieian-Kopaei, M.: *Clin. Ter.*, 165(1): 7-11 (2014).