

## DETECTION OF GLANDULAR CHORISTOMA IN AN MESENTERIC LYMPH NODE FROM AN ADULT CROSSBRED GOAT WITH PARATUBERCULOSIS: A CASE STUDY

RAJENDRA KUMAR, T.<sup>1</sup> AND TRIPATHI, B. N.<sup>2</sup>

<sup>1</sup>Department of Veterinary Pathology, Veterinary College, Nandinagar, Bidar, 585401, Karnataka;

<sup>2</sup>National Research Centre on Equines, Sirsa Road, Hisar, 125001, Haryana.

E. mail: [drrajendra4428@gmail.com](mailto:drrajendra4428@gmail.com). Cell: 09972701216

Received: April 27, 2017; Accepted: May 26, 2017

**Abstract:** *The present report describes the accidental detection of ectopic intestinal gland like structures with interspersed goblet cells in a mesenteric lymph node from an crossbred adult goat, which was infected with *Mycobacterium avium* subsp. *paratuberculosis*. The histomorphological features reminded intestinal epithelium, and glandular choristoma was diagnosed. This report is to our knowledge, the first description of glandular choristoma in an Indian goat with paratuberculosis.*

**Key words:** Glandular choristoma Paratuberculosis, Goat

### INTRODUCTION

Choristoma is present in normal tissue at any ectopic location. These pathologic changes have also been reported in various sites from a large range of domestic animal species [1]. In goat, several cases are known that involve its development in mammary tissues, vulva [2], cervix [3] and in the thyroid gland [4]. In man, glandular choristomas have been reported both in association with neoplastic tissue or independently [5]. Nevertheless, to the best our knowledge, there is only one description of presence of glandular inclusions in the mesenteric lymph node of paratuberculosis goat [6]. This is the second reported case of glandular choristoma in caprine mesenteric lymph node with paratuberculosis.

### MATERIAL AND METHODS

In the course of field study on paratuberculosis, a cross bred adult goat with emaciated body condition

without diarrhea was presented for slaughter in the slaughter house, Bareilly. Intestine of this animal showed thickening and corrugation of mucosa and enlarged, edematous mesenteric lymph node. This was collected and transferred to 10% neutral buffered formalin. The tissue was fixed for 48 hrs, washed, dehydrated and embedded in paraffin wax. Sections (5µm) were stained with haematoxylin and eosin and Ziehl –Neelsen stain.

The pieces of small intestine adjacent to the ileo-caecal valve (ICV) and mesenteric lymph node (MLN) were separated for PCR and bacterial isolation and kept at -20°C until use. Extraction of DNA from tissue sample was performed as per the method described previously with slight modification [7]. The final elute containing genomic DNA was preserved at -20°C. The primers (251-F-5'GCAAGACGTTTCATGGGAAGT3' and 251-R-5'GCGTAACTCAGCGAACAACA3') flanking a region of 203 bp of 251 gene locus were designed

commercially [8]. The genomic DNA isolated from tissues was used as a template for PCR amplification. PCR reaction mixture (50 µl) contained 1X PCR buffer, 2 mM MgCl<sub>2</sub>, 200 µM dATP, dGTP, dCPT and dTTP, 0.5U Taq DNA polymerase, 1 µM of primers and 2 µl of template DNA. PCR amplification was carried out in an automated thermal cycler through initial denaturation at 94°C for 5 min followed by 35 cycles each of denaturation at 94°C for 45 sec, annealing at 55°C for 1 min, synthesis at 72°C for 1 min and final elongation at 72°C for 1 min. The PCR products were analyzed by visualization of desired size of DNA band in the ethidium bromide stained 1.5% agarose gel [9].

## RESULTS

On examination post-slaughter, distal small intestine mucosa was thickened with corrugation (Fig. 1) and ileocaecal and mesenteric lymph nodes were enlarged. In one of the anterior mesenteric lymph node, cut surfaces showed a few grayish-white foci (Fig. 2). This goat was suspected for paratuberculosis infection. Scrapping smears from ICV and MLN failed to reveal acid-fast bacilli. On histological examination, intestinal villi were club shaped and were thickened due to infiltration of greater number of lymphocytes and macrophages (Fig. 3). Aggregates of macrophages were occasionally observed in the lamina propria. There was no evidence of any malignant changes in the villous or crypt epithelium or in the Peyer's patches. The sample was negative for bacterial culture and ZN staining and positive for 251 gene locus PCR and specific amplified product of 203bp was obtained (Fig. 8).

The mesenteric lymph node showed thickened capsule and scattered infiltration of macrophages in the cortical area. Intestinal crypts (intestinal glands) like structures were located at three to four places in the subcapsular region or little down in the cortical region (Figs. 4,5). These glandular structures were lined by columnar epithelium interspersed with goblet cells having vacuolated cytoplasm (Figs. 6,7). These glandular structures did not show any anaplastic changes typical of malignant tumours. The glandular structures were not observed in the medullary region.

## DISCUSSION

The development of an ectopic-non neoplastic normal tissue in an abnormal location is known as choristoma. The occurrences of choristoma are described as very infrequent [10]. This is the second report of the glandular choristoma in caprine lymph node, formed by glandular structures. This goat was suspected for paratuberculosis infection on gross and histopathological examination and it was found positive for 251 gene locus tissue PCR. In the mesenteric lymph node, intestinal crypts (intestinal glands) like structures were observed, which were located at three or four places in subcapsular regions or little down in the cortical regions. The paracortex and corticomedullary junction were infiltrated with macrophages. In previous report, a glandular choristoma found in mesenteric lymph node of Payoya goat with paratuberculosis would appear to represent the first reported case in domestic animals [6]. The author described the presence of glandular structures randomly both in the cortex and medulla and all glandular epithelial cells reacted to the anticytokeratin AE1/AE3 polyclonal antibody

---

### Explanation of figures:

**Fig. 1:** Intestine showing thickening and slight corrugation of mucosa

**Fig. 2:** Swollen Mesenteric lymph node and cut surface showing grayish white foci

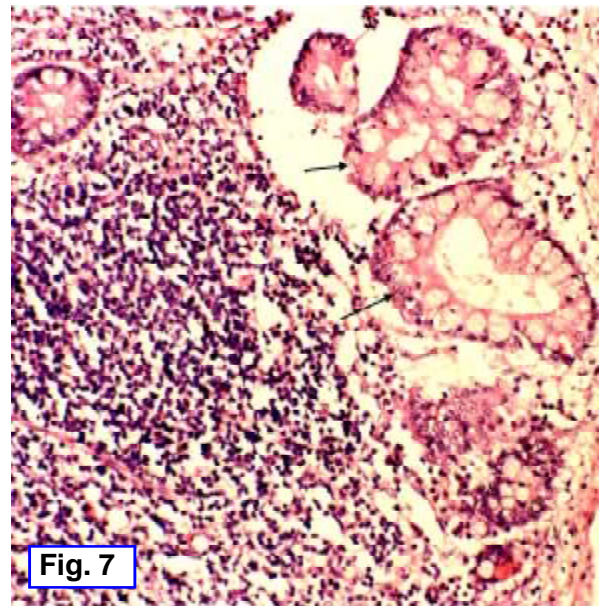
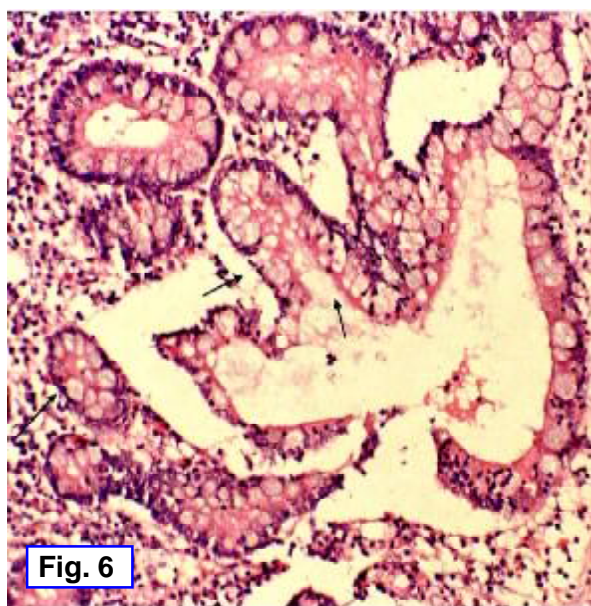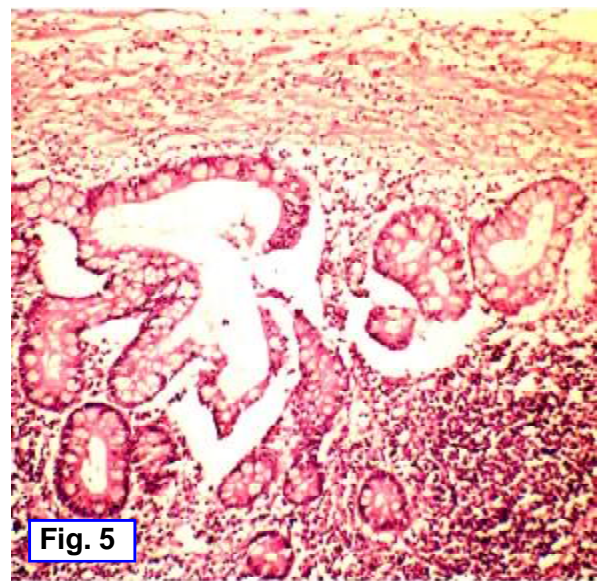
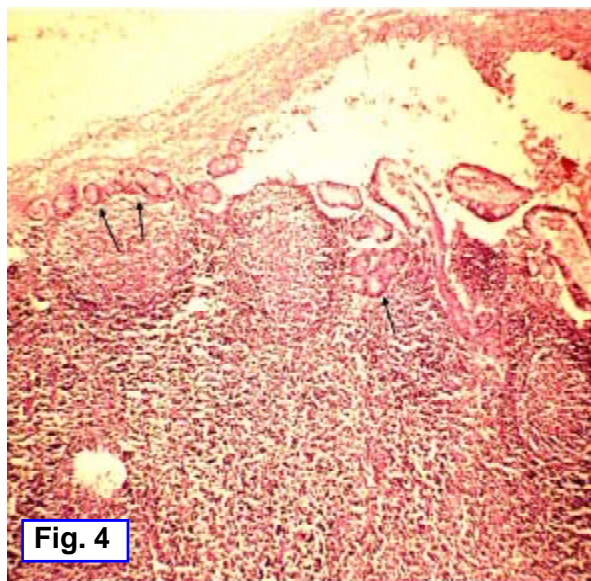
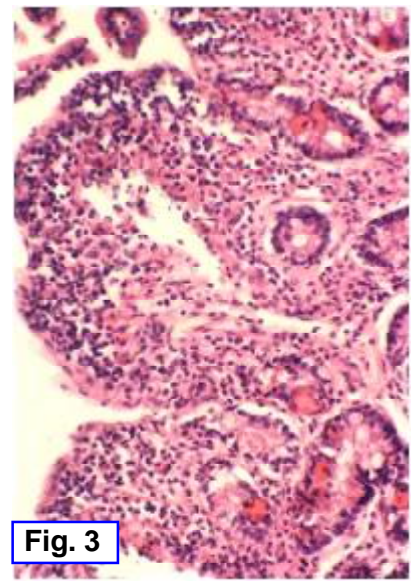
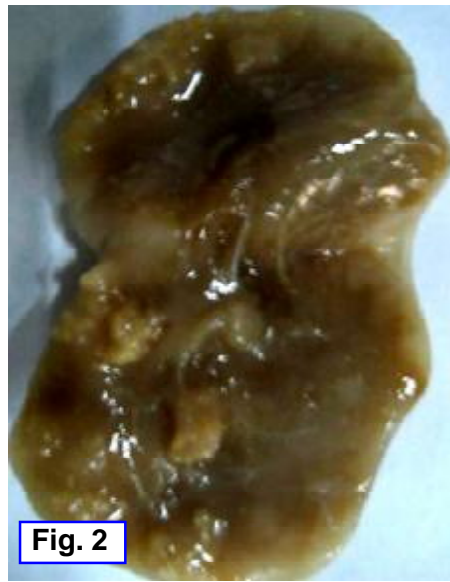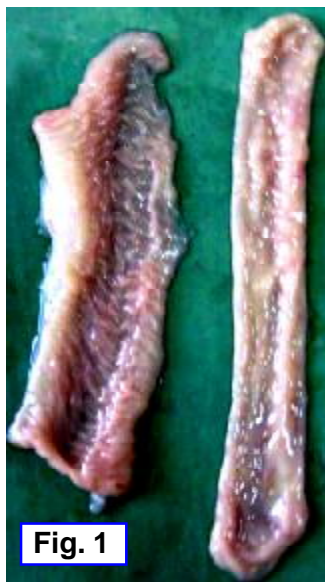**Fig. 3:** Ileum of goat showing club shaped villi infiltrated with macrophages and lymphocytes. HE×380.

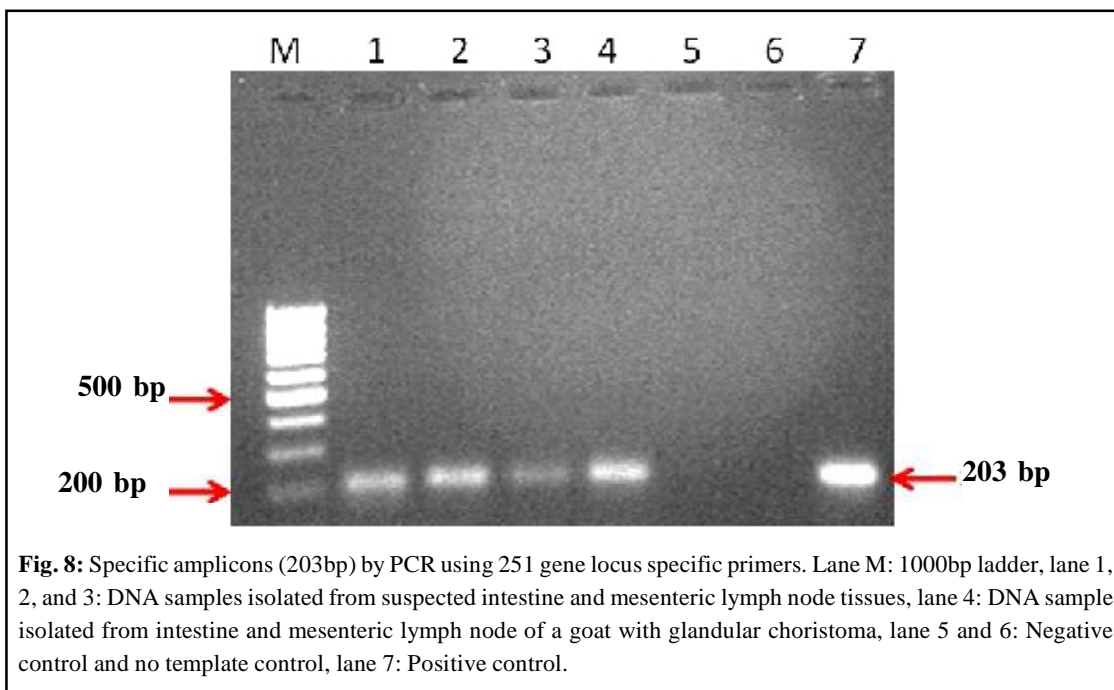
**Fig. 4:** Mesenteric lymph node showing thickened capsule and presence intestinal glandular structures in the subcapsular areas. HE×60

**Fig. 5:** Mesenteric lymph node showing well developed glandular structures lined by columnar cells and vacuolated goblet cells without anaplasia. HE×150

**Fig. 6:** Higher magnification of figure 5. HE×240

**Fig. 7:** Higher magnification of figure 5. HE×240





immunohistochemical examination and confirmed the glandular epithelial nature of the epithelial cells. In the present report, glandular structures were noticed only in the cortex not in the medullary region. Unfortunately, the affected lymph node was used for histological study and extraction of DNA. Because of this, immunohistochemistry could not be carried out as material was not available.

Pathogenesis of these intestinal glandular inclusions within the lymph node is not well understood. However different theories have been proposed by earlier authors for explaining the development of these inclusions [10]. In the present case, the mechanism underlying the development of these inclusions is unclear, but possibilities include, involvement of nonspecific factor, inflammation or inductive substance, sloughing of the epithelium or haematogenic or lymphatic dissemination. The earlier reported case [6] was thought to be associated with the regional inflammatory process as a result of paratuberculosis infection.

#### ACKNOWLEDGEMENTS

The authors are thankful to Director, Indian Veterinary Research Institute, Izatnagar (UP) for providing support and assistance to carry out the research work.

#### REFERENCES

- [1] MacLachlan, N. J. and Kennedy, P. C.: *Tumors in Domestic Animals*, (Meuten, D.J. ed.), 4<sup>th</sup> edit, Iowa State Press, Iowa, pp 557-567 (2002).
- [2] Gameel, A.A., Ramadan, R.O. and Dafalla, E A.: *Zentralblatt für Veterinärmedizin Reihe A* 39: 470-475 (1992).
- [3] Ramadan, R.D. and Hassan, A.M.: *Aust. Vet. J.*, 51: 362 (letter) (1975).
- [4] Roy, K.S., Saigal, R.P., Nanada, B.S. and Nagpal, S.K. *Anatomischer Anzeiger*, 139: 158-164 (1976).
- [5] von Rahden, B.H., Stein, H.J., Becker, K. and Siewert, R.J.: *Dig. Surgery*, 22: 107-112 (2005).
- [6] Gómez-Laguna, J., Carrasco, L., Gordon, A., Millán, Y., Garrido, M.R.F., Rodriguez-Solera, S., Espinosa de IosMonteros and Martin de las Mulas, J.: *J. Comp. Pathol.*, 136: 193-196 (2007).
- [7] Tripathi, B.N., Sivakumar Periasamy, Paliwal, O.P. and Singh, N.: *Vet. Microbiol.*, 116: 129-137 (2006).
- [8] Rajeev, S., Zhang, Y., Sreevatsan, S., Alifiya, S., Motiwal, A., Byrum, B.: *Vet. Microbiol.*, 105: 215-221 (2005).
- [9] Sambrook, J. and Russel, D.W.: *Molecular Cloning- A laboratory manual*. Cold Spring laboratory Press, New York, USA (2001).
- [10] Quesada, O., Suárez-Bonnet, A., Andrada, M., Fernández, A., de losMonteros, A. E.: *J. Com. Pathol.*, 142: 218-222 (2010).